

Effectiveness of Oral Ivermectin Treatment in Cases Unresponsive to Classical *Demodex* Blepharitis Treatment

Klasik *Demodeks* Blefarit Tedavisine Yanıtsız Olgularda İvermektin Ekinliği

✉ Oktay Alver¹, ✉ Derya Doğanay², ✉ Selim Doğanay³

¹Bursa Uludağ University Faculty of Medicine, Department of Medical Microbiology, Bursa, Türkiye

²Çekirge State Hospital, Clinic of Ophthalmology, Bursa, Türkiye

³Bursa Uludağ University Faculty of Medicine, Department of Ophthalmology, Bursa, Türkiye

Cite this article as: Alver O, Doğanay D, Doğanay S. Effectiveness of oral ivermectin treatment in cases unresponsive to classical *Demodex* blepharitis treatment. Türkiye Parazitol Derg. 2025;49(4):168-72.

ABSTRACT

Objective: *Demodex* blepharitis is a common inflammatory eye condition caused by an overgrowth of *Demodex* mites on the eyelids, and lash follicles, Zeiss' glands and Meibomian glands that is often overlooked. The aim of this study is to investigate the effectiveness of ivermectin tablet oral treatment in cases unresponsive to classical *Demodex* blepharitis treatment.

Methods: A total of 35 patients (17 men and 18 women) with chronic symptomatic blepharitis were included in the study. Patients were admitted to Çekirge State Hospital and Bursa Dünüygöz Hospital Ophthalmology Clinics between December 12, 2017, and April 15, 2021, and were found to have Cylindrical dandruff resistant to classical *Demodex* blepharitis treatment. Following the classical *Demodex* treatment in these cases, oral ivermectin was started in two doses of 0.2 mg/kg, 30 days apart. The presence of *Demodex* in the eyelashes, ocular surface disease index (OSDI) score was evaluated before the classical *Demodex* blepharitis treatment and after the ivermectin treatment. A detailed biomicroscopic eye examination was performed in all cases.

Results: Of the total 35 patients admitted to the hospital, 17 (48.6%) were men [mean \pm standard deviation (SD): 48.41 \pm 15.62, min-max: 18-75] and 18 (51.4%) were women (mean \pm SD: 51.17 \pm 14.98, min-max: 19-73). There was no statistically significant difference between men and women in terms of average age ($p=0.598$). OSDI scoring mean \pm SD values before classical *Demodex* blepharitis treatment and after oral ivermectin treatment were 77.47 \pm 5.74 and 6.69 \pm 4.71, respectively.

Conclusion: In the treatment of *Demodex* related blepharitis, the use of oral ivermectin is an effective treatment option in cases that do not respond to classical treatment.

Keywords: *Demodex* sp., blepharitis, oral ivermectin, Bursa, Türkiye

ÖZ

Amaç: *Demodeks* blefariti, göz kapaklarında, kirpik diplerinde, Zeiss bezlerinde ve Meibomian bezlerinde *Demodeks* akarlarının aşırı çoğalmasıyla oluşan ve genellikle gözden kaçan yaygın bir göz iltihabı rahatsızlığıdır. Bu çalışmanın amacı klasik *Demodeks* blefarit tedavisine yanıtsız olgularda ivermektin tablet oral tedavisinin etkinliğini araştırmaktır.

Yöntemler: Çalışmaya kronik semptomatik blefarit tanısı almış toplam 35 hasta (17 erkek ve 18 kadın) dahil edildi. Çalışmaya Çekirge Devlet Hastanesi ve Bursa Dünüygöz Hastanesi Göz Hastalıkları Klinikleri'ne 12 Aralık 2017 ile 15 Nisan 2021 tarihleri arasında başvuran ve klasik *Demodeks* blefariti tedavisine dirençli Cylindrical dandruff 'lu hastalar dahil edildi. Bu olgularda *Demodeks* klasik tedavisinin ardından 30 gün arayla 0,2 mg/kg'lık iki dozda oral ivermektin başlandı. Klasik *Demodeks* blefariti tedavisi öncesi ve ivermektin tedavisi sonrası kirpiklerde *Demodeks* varlığı, oküler yüzey hastalığı indeksi (OSDI) skoru değerlendirildi. Tüm olgulara detaylı biyomikroskopik göz muayenesi yapıldı.

Bulgular: Hastaneye kabul edilen toplam 35 hastanın 17'si (%48,6) erkek [ortalama \pm standart sapma (SS): 48,41 \pm 15,62, min-maks: 18-75] ve 18'i (%51,4) kadındı (ortalama \pm SS: 51,17 \pm 14,98, min-maks: 19-73). Erkekler ve kadınlar arasında yaş ortalamaları açısından istatistiksel olarak anlamlı bir fark saptanmadı ($p=0,598$). Klasik *Demodeks* blefariti tedavisi öncesi ve oral ivermektin tedavisi sonrası OSDI skorlama ortalama \pm SS değerleri sırasıyla 77,47 \pm 5,74 ve 6,69 \pm 4,71 idi.

Sonuç: *Demodeks* ilişkili blefarit tedavisinde klasik tedaviye yanıt vermeyen olgularda oral ivermektin kullanımının etkili bir tedavi seçeneği olabileceği kanaatine varıldı.

Anahtar Kelimeler: *Demodeks* sp., blefarit, oral ivermektin, Bursa, Türkiye



Received/Geliş Tarihi: 16.03.2025 Accepted/Kabul Tarihi: 26.08.2025 Epub: 11.09.2025 Publication Date/Yayınlanma Tarihi: 01.12.2025

Address for Correspondence/Yazar Adresi: Assoc. Prof. Oktay Alver, Bursa Uludağ University Faculty of Medicine, Department of Medical Microbiology, Bursa, Türkiye

E-mail/E-Posta: oktayalver@uludag.edu.tr **ORCID ID:** orcid.org/0000-0002-5559-3590



©Copyright 2025 Turkish Society for Parasitology - Available online at www.turkiyeparazitolog.org

This article is distributed under the terms of the Creative Commons Attribution-NonCommercial (CC BY-NC-ND) 4.0 International License.

INTRODUCTION

Demodex mites are arthropods that belong to the class Arachnida, the order Prostigmata and family Demodicidae (1). It is the most common host-dependent microscopic ectoparasite in humans (2). The family Demodicidae is represented by eight genera and 116 species that live as parasites on mammals (3), while only two of them (*Demodex folliculorum* and *Demodex brevis*) live in the pilosebaceous units of human skin (4). While *D. folliculorum* is 0.35-0.4 mm long and lives singly or in groups in hair follicles, *D. brevis* is 0.15-0.2 mm long and usually lives alone in the depths of the sebaceous glands. In the eyelids (Zeiss' glands) and the lobules of the eyelid glands (Meibomian glands) (5,6) and cause anterior and posterior blepharitis, respectively; *D. folliculorum* and *D. brevis* (7). *Demodex* blepharitis is a chronic inflammatory disease that can cause severe eye problems affecting the lid margin and ocular surface (7). The primary cause of demodectic blepharitis is no doubt the increase in the number of *Demodex* mites in the area. The plug and tension that occurs in the follicles due to increased number of *Demodex* mites can not only cause deformities in the eyelashes and dysfunction in the Meibomian glands, but also can cause a foreign body sensation and the development of an immune response against the chitin skeleton, as it deepens into the Meibomian glands (8). Accordingly, if left untreated, it may lead to severe lesions such as eyelid and eyelash abnormalities, blurred vision and corneal damage (9). It has been reported that 41.6-81.25% of blepharitis patients have concurrently developed symptoms related to *Demodex* mites, and this rate reaches 100% among people over 70 years (10).

The aim of this study is to probe further the response of systemic ivermectin treatment in blepharitis cases with *Demodex* infestation that do not respond to the classical treatment.

METHODS

The study was carried out in Bursa, the fourth most industrialized city in Türkiye. A total of 35 patients (17 men and 18 women) aged between 18 and 75 years, with chronic blepharitis, diagnosed with Cylindrical dandruff (CD) resistant to classical *Demodex* blepharitis treatment, were admitted to the Ophthalmology Clinics in Çekirge State Hospital and Bursa Uludağ University Faculty of Medicine, Bursa between December 12, 2017 and April 15, 2021, were included in the study. Data on demographic (age and gender), clinical characteristics (diabetes, hypertension, etc.), ocular symptoms (dry eye symptoms, eyelash loss, ingrown eyelashes, etc.), *Demodex* mite density, and ocular medications were obtained from patient records.

Ethical approval was obtained from the Clinical Research Ethics Committee of Bursa Uludağ University (permission no: 2021-14/18, date: 13/10/2021).

Collection and Examination of the Samples

A specialist medical parasitologist examined the eyelash samples. A total of 12 eyelash samples, three from the upper and lower lids of each eye, were taken by epilation method. Before taking samples, care was taken to avoid cosmetic products such as mascaras, eye shadows, eye liners. Eyelashes were placed on the slide, and then 2-3 drops of Hoyer's medium were dropped on them and covered with a coverslip. The area was scanned using a light microscope with x40 magnification, and then inspected with a slightly closed diaphragm at x10 and x40 magnification, and

the findings were noted. Participants whose sample materials are found to contain at least one egg, larva, nymph or mature forms of *D. folliculorum* or *D. brevis* were considered positive for *Demodex* (Figure 1).

Evaluation of Ocular Surface Parameters

The ocular surface examinations were performed in the following order: Slit lamp examination was conducted on palpebral margin, and checked for any congestion and shape irregularity of palpebral margin, blockage on the opening of the Meibomian gland, and backward displacement of the Meibomian gland orifice opening were evaluated using the scoring criteria reported in (Figure 2) (11).

Statistical Analysis

Statistical analysis of data was carried out using IBM SPSS Version 28.0 (IBM Corp. Released 2021. IBM SPSS Statistics for Windows, Version 28.0. Armonk, NY: IBM Corp). The descriptive statistics are given as mean and standard deviation for quantitative data, and frequency and percentage for the qualitative data. Shapiro-Wilk test was used to examine the normality of variables. It is found that the collected data samples are normally distributed. T-test was used to compare the comparison of the two independent groups, and the paired t-test was used to compare the dependent variables. Pearson correlation coefficient was used to evaluate the relationship between variables. The statistical significance level was determined to be 0.05.

RESULTS

Of the total of 35 cases, 17 (48.6%) were men [mean \pm standard deviation (SD): 48.41 \pm 15.62, min-max: 18-75] and 18 (51.4%) were women (mean \pm SD: 51.17 \pm 14.98, min-max: 19-73). There was no statistically significant difference between men and

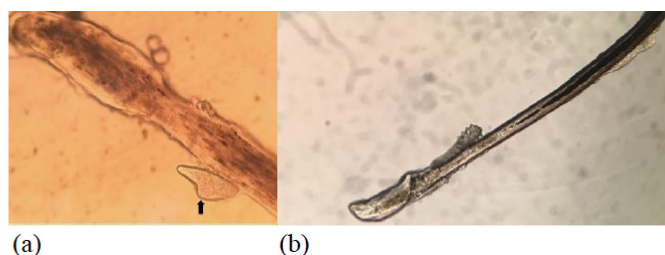


Figure 1. (a) *Demodex folliculorum* egg form (arrow) and **(b)** *Demodex folliculorum* adult located on an eyelash follicle under light microscope

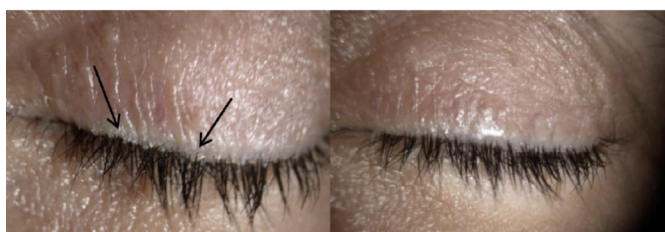

Figure 2. A *Demodex*-positive patient with Cylindrical dandruff (arrow) before and 2 months after ivermectin treatment

women in terms of average age ($p=0.598$). All patients were over 18 years of age, while their mean age was 49.8 ± 15.1 years. At their first visit to the clinic, 27 (77.1%) of patients were found to have dry eye complaints, 4 (11.4%) have eyelash loss, 3 (5.7%) have ingrown eyelashes (trichiasis), and 2 (5.7%) have itching complaints. In the study, each patient stated that they had had chalazion at least once. One patient stated that she was operated on once for chalazion, and another patient stated that she was operated on 4 times. Biomicroscopic examination revealed anterior blepharitis in 5 (14.3%) patients, posterior blepharitis in 6 (17.1%), anterior and posterior blepharitis in 23 (65.7%), and allergic conjunctival papillae in 5 (14.3%). *D. folliculorum* was detected in 32 of 35 cases (91.4%). Coexistence of *D. folliculorum* and *D. brevis* was detected in three patients (8.6%). *Demodex* sp. was detected in all CD patients in the biomicroscopic study, while keratitis was present in three patients. Three patients were taking prescribed medication for diabetes and hypertension, while two patients were taking medication for hypertension only. In 18 of the cases, *Demodex* sp. was found on the upper and lower eyelids of both eyes. There was no significant relationship between age and *Demodex*/eyelash in women ($r=0.117$; $p=0.644$), men ($r=-0.175$; $p=0.503$) and in all patients in general ($r=-0.025$; $p=0.887$). Before the application of ivermectin, the patients were treated doxycycline (tetradox® capsule 100 mg) 2x1 oral for 20 days, levofloxacin (levolon® 0.5% drops) 4x1 for two months, oxytetracycline hydrochloride+polymyxin b sulfate eye ointment (terramycin® 5 mg/10.000 IU eye ointment) 2x1 for two months, pilocarpine (pilosed® 2% drops) (massage to the eyelash roots with earwax 5 times a day) for two months, eye wash shampoo containing tea tree oil (TTO thermal®) (every evening eyelid cleaning) for six months. *Demodex* sp. was detected in the eyelash examinations of patients whose blepharitis symptoms did not completely disappear at the end of the second month despite the previous treatment given above. Two doses of oral ivermectin tablet (0.2 mg/kg) were administered, one month apart. As shown in Figure 1, after two months of oral ivermectin treatment, the blepharitis symptoms completely resolved and the parasite load was reduced in all patients. A statistically significant difference was found between ocular surface disease index (OSDI) values before and after treatment ($p<0.001$).

DISCUSSION

In a multicenter retrospective study involving six optometry and ophthalmology clinics in the USA, the prevalence of *Demodex* blepharitis was reported as 57.7% (12). Many studies have reported an increase in the number of mites with age (13) which was explained by the decrease in the activity of the Rusiecka-Ziółkowska et al. (14) glands with aging. In the studies conducted on patients with blepharitis, as discussed by Sędzikowska et al. (15), Mongi et al. (16), and Wesolowska et al. (17) that they detected the highest *Demodex* sp. infestation rate on patients aged 50 years and above ($p<0.005$), 60 years and over ($p<0.001$), and 70 years and over ($p<0.001$), respectively. This may be associated with the lack of good eyelid hygiene in elderly patients and certain factors such as immunosuppression, vasodilatation factors, diabetes mellitus, and/or sebaceous gland hyperplasia (18) or malignancy, or malnutrition (19). As age increases, *Demodex* infestation rates tend to rise not only in the eyelashes but also on the face and other areas of the body (18). In the present study, the

highest *Demodex* sp. infestation rate was determined in people aged 45 and over (68.5%), while no significant differences were found between age and *Demodex* sp. This finding was consistent with the results of numerous previous studies ($p=0.598$) (20,21). Although there are many studies in the literature relating the number of *Demodex* to the gender of the patients, it still remains controversial. However, in this study, no relationship was found between the number of *Demodex* and the gender of the patients, supporting the results discussed by Lee et al. (6) and Kemal et al. (21). In other words, Okyay et al. (22) reported that *Demodex* sp. infestation was higher in men, while Forton et al. (23) and Zeytun (24) reported higher infestation rates in women, and Zhao et al. (25) reported equal rates in men and women. These differences between studies may be associated with the differences in skin care, type of skin, increase in the number of mites and hygiene practices of patients included in the study. Itching, burning sensation, excessive lacrimation, feeling of heaviness in the eyelids and mucous discharge are frequently encountered symptoms in blepharitis cases with *Demodex* infestation (26). Kheirkhah et al. (27) reported decreased vision in 50% of blepharitis cases caused by *Demodex* sp., and Meibomian gland dysfunction in 83.3%. Gao et al. (28) reported that they detected eyelash loss in 45.5% of the eyelid demodicosis cases, and Meibomian gland dysfunction in 63.6%. It is stated that the microabrasions caused by *D. folliculorum* at the base of the eyelashes cause reactive hyperkeratinization and epithelial hyperplasia, resulting in the formation of CD, which is accepted as pathognomonic for *D. folliculorum* infestation (28,29). In Thailand, Kasetsuwan et al. (30) reported that they detected CD by microscopy in 69% and 15.5% of cases with and without ocular *Demodex* infestation, respectively. It has been stated that CD formation may be clinically valuable in monitoring the response to treatment in patients with chronic blepharitis (31). In the present study, all patients diagnosed with CD with chronic blepharitis, resistant to classical treatments, were found to be *Demodex* sp. positive. The number of *Demodex* sp. per eyelash before treatment was 1.63 (652/398). Today, the ambiguity in etiopathogenesis makes the treatment of blepharitis complicated. One of the primary aims of ocular demodicosis treatment is to reduce parasitic overpopulation in the lids and eyelashes and reduce inflammation by providing a better environment for the eye surface. There are many treatment options in the literature for this purpose. Although XDEM VY™ (lotilaner ophthalmic solution) is an FDA-approved preparation for the treatment of *Demodex* blepharitis, it is not being used in our country. In the treatment of blepharitis, the American Academy of Ophthalmology Blepharitis Preferred Practice Pattern recommends a combination of antibiotics, topical anti-inflammatories, and daily eyelid hygiene (32). The most frequently used approach to the eyelid hygiene is the use of gel, cream and shampoo forms of TTO, which is obtained by steam distillation from the leaves of *Melaleuca Alternifolia* (Indian laurel), or its most important acaricidal component, terpinen-4-ol (26). In previous studies Junk et al. (33) reported a remission rate of 71.6% in the fourth week of combined treatment of oral ivermectin and metronidazole (3x250 mg/day for three weeks) in patients with anterior blepharitis and valve lesions caused by *Demodex* sp. and also showed that combined treatment was more effective than ivermectin alone. In the treatment of inflammation on the palpebral edges, it was reported that local application of yellow mercury ointment, sulfuric ointment, anticholinesterase,

antifungal drugs or antibiotics provided clinical improvement, but the best results were obtained after the application of metronidazole, mercury and erythromycin ointments (33). Holzchuh et al. (34), treated their patients with one dose of oral ivermectin (200 µg/kg) and repeated it after 7 days, and reported that the treatment had improved the symptoms of chronic blepharitis, with a 35.3% mite eradication rate. Symptoms caused by *Demodex* mites are difficult to treat and can take several months. This can be partly explained by the fact that the life cycle of *Demodex* sp. is approximately 14 days and the total life span is several weeks (4). Therefore, in this study, 8 weeks of treatment (approximately 4 life cycles of *Demodex*) were administered to evaluate recurrence of infestation. In another study, the mite eradication rate was expressed as 36% after four months of TTO shampoo treatment at low concentration (7.5%) to minimize the risks of possible side effects of TTO (35). In our study, there was little improvement in symptoms after the classical treatments of *Demodex* chronic blepharitis, when the presence of *Demodex* sp. was detected and a single dose of ivermectin was prescribed. No drug-related side effects were observed after treatment. At the end of the second month, improvement in the symptoms of blepharitis and a significant decrease in parasite load were observed. OSDI score is usually (generally) used in ophthalmology practice as it can directly indicate the degree of ocular surface inflammation. Zhang et al. (20) and Zeytun (24) reported that they found a significant increase in OSDI score in the ocular *Demodex* positive patient group. Pan and Chen (36) reported a significant correlation between *Demodex* count and OSDI score. Liu et al. (8) stated that there was a significant relationship between the number of *Demodex*, the OSDI score, and the severity of eye disease. Mergen et al. (37) reported that they found a negative relationship between the *Demodex* count and OSDI scores in patients with seborrheic blepharitis. In this study, a significant relationship was also found between the *Demodex* count and the OSDI score by performing correlation analysis.

CONCLUSION

Our study shows that oral ivermectin treatment may be beneficial especially in cases that do not respond to classical *Demodex* blepharitis treatments. However, we think that our results should be supported by more comprehensive randomized and prospective studies.

*Ethics

Ethics Committee Approval: Ethical approval was obtained from the Clinical Research Ethics Committee of Bursa Uludağ University (permission no: 2021-14/18, date: 13/10/2021).

Informed Consent: Retrospective study.

Footnotes

*Authorship Contributions

Surgical and Medical Practices: A.O., D.D., S.D., Concept: A.O., D.D., S.D., Design: A.O., D.D., Data Collection or Processing: A.O., D.D., Analysis or Interpretation: A.O., S.D., Literature Search: A.O., D.D., Writing: A.O., S.D.

Conflict of Interest: No conflict of interest was declared by the authors.

Financial Disclosure: The authors declared that this study received no financial support.

REFERENCES

1. Basta-Juzbasić A, Subić JS, Ljubojević S. *Demodex folliculorum* in development of dermatitis rosaceiformis steroidica and rosacea-related diseases. Clin Dermatol. 2002; 20: 135-40.
2. Murube J. *Demodex hominis*. Ocul Surf. 2015; 13: 181-6.
3. Izdebska JN, Rolbiecki L. A new genus and species of demodecid mites from the tongue of a house mouse *Mus musculus*: description of adult and immature stages with data on parasitism. Med Vet Entomol. 2016; 30: 135-43.
4. Rather PA, Hassan I. Human *Demodex* mite: the versatile mite of dermatological importance. Indian J Dermatol. 2014; 59: 60-6.
5. English FP, Nutting WB. Demodicosis of ophthalmic concern. Am J Ophthalmol. 1981; 91: 362-72.
6. Lee SH, Chun YS, Kim JH, Kim ES, Kim JC. The relationship between *Demodex* and ocular discomfort. Invest Ophthalmol Vis Sci. 2010; 51: 2906-11.
7. Cheng AM, Sheha H, Tseng SC. Recent advances on ocular *Demodex* infestation. Curr Opin Ophthalmol. 2015; 26: 295-300.
8. Liu J, Sheha H, Tseng SC. Pathogenic role of *Demodex* mites in blepharitis. Curr Opin Allergy Clin Immunol. 2010; 10: 505-10.
9. Ricardo-Gonzalez RR, Kotas ME, O'Leary CE, Singh K, Damsky W, Liao C, et al. Innate type 2 immunity controls hair follicle commensalism by *Demodex* mites. Immunity. 2022; 55: 1891-908.e12.
10. Kabataş N, Doğan AŞ, Kabataş EU, Acar M, Biçer T, Gürdal C. The effect of *Demodex* infestation on blepharitis and the ocular symptoms. Eye Contact Lens. 2017; 43: 64-7.
11. Schiffman RM, Christianson MD, Jacobsen G, Hirsch JD, Reis BL. Reliability and validity of the ocular surface disease index. Arch Ophthalmol. 2000; 118: 615-21.
12. Trattler W, Karpecki P, Rapoport Y, Sadri E, Schachter S, Whitley WO, et al. The prevalence of *Demodex* blepharitis in US eye care clinic patients as determined by collarettes: a pathognomonic sign. Clin Ophthalmol. 2022; 16: 1153-64.
13. Litwin D, Chen W, Dzika E, Korycińska J. Human permanent ectoparasites; recent advances on biology and clinical significance of *Demodex* mites: narrative review article. Iran J Parasitol. 2017; 12: 12-21.
14. Rusiecka-Ziółkowska J, Nokić M, Fleischer M. *Demodex* – an old pathogen or a new one? Adv Clin Exp Med. 2014; 23: 295-8.
15. Sędzikowska A, Osęka M, Grytner-Zięcina B. Ocular symptoms reported by patients infested with *Demodex* mites. Acta Parasitol. 2016; 61: 808-14.
16. Mongi F, Laconte L, Casero RD. Ácaros del género *Demodex*: ¿parásitos colonizadores de personas sanas o asociados a patología ocular? [*Demodex* genus: colonizing parasites of healthy people or mites associated with ocular pathology?]. Rev Argent Microbiol. 2018; 50: 369-73. Spanish.
17. Wesolowska M, Knysz B, Reich A, Blazejewska D, Czarnecki M, Gladysz A, et al. Prevalence of *Demodex* spp. in eyelash follicles in different populations. Arch Med Sci. 2014; 10: 319-24.
18. Chudzicka-Strugała I, Gołębiowska I, Brudecki G, Elamin W, Zwoździak B. Demodicosis in different age groups and alternative treatment options-a review. J Clin Med. 2023; 12: 1649.
19. Kaya S, Selimoglu MA, Kaya OA, Ozgen U. Prevalence of *Demodex folliculorum* and *Demodex brevis* in childhood malnutrition and malignancy. Pediatr Int. 2013; 55: 85-9.
20. Zhang XB, Ding YH, He W. The association between *Demodex* infestation and ocular surface manifestations in meibomian gland dysfunction. Int J Ophthalmol. 2018; 11: 589-92.

21. Kemal M, Sümer Z, Toker MI, Erdoğan H, Topalkara A, Akbulut M. The prevalence of *Demodex folliculorum* in blepharitis patients and the normal population. *Ophthalmic Epidemiol.* 2005; 12: 287-90.
22. Okyay P, Ertabaklar H, Savk E, Erfug S. Prevalence of *Demodex folliculorum* in young adults: relation with sociodemographic/hygienic factors and acne vulgaris. *J Eur Acad Dermatol Venereol.* 2006; 20: 474-6.
23. Forton F, Germaux MA, Brasseur T, De Liever A, Laporte M, Mathys C, et al. Demodicosis and rosacea: epidemiology and significance in daily dermatologic practice. *J Am Acad Dermatol.* 2005; 52: 74-87.
24. Zeytun E. *Demodex* (Acari: Demodicidae) infestation in the elderly and its relationship with the skin parameters such as moisture, pH, and temperature: a cross-sectional study. *Turkish Journal of Geriatrics.* 2017; 20: 142-50.
25. Zhao YE, Guo N, Xun M, Xu JR, Wang M, Wang DL. Sociodemographic characteristics and risk factor analysis of *Demodex* infestation (Acari: Demodicidae). *J Zhejiang Univ Sci B.* 2011; 12: 998-1007.
26. Bhandari V, Reddy JK. Blepharitis: always remember *Demodex*. *Middle East Afr J Ophthalmol.* 2014; 21: 317-20.
27. Kheirkhah A, Casas V, Li W, Raju VK, Tseng SC. Corneal manifestations of ocular *Demodex* infestation. *Am J Ophthalmol.* 2007; 143: 743-9.
28. Gao YY, Di Pascuale MA, Elizondo A, Tseng SC. Clinical treatment of ocular demodicosis by lid scrub with tea tree oil. *Cornea.* 2007; 26: 136-43.
29. Luo X, Li J, Chen C, Tseng S, Liang L. Ocular demodicosis as a potential cause of ocular surface inflammation. *Cornea.* 2017; 36(Suppl 1): S9-14.
30. Kasetsuwan N, Kositphipat K, Busayarat M, Threekhan P, Preativatanyou K, Phumee A, et al. Prevalence of ocular demodicosis among patients at tertiary care center, Bangkok, Thailand. *Int J Ophthalmol.* 2017; 10: 122-7.
31. Savla K, Le JT, Pucker AD. Tea tree oil for *Demodex* blepharitis. *Cochrane Database Syst Rev.* 2020; 6: CD013333.
32. Garratt S. American Academy of Ophthalmology. Blepharitis Preferred Practice Pattern®. San Francisco (CA): American Academy of Ophthalmology; 2023. p. 50-86.
33. Junk AK, Lukacs A, Kampik A. Lokale anwendung von metronidazol-gel als wirksame therapiealternative in der behandlung der chronischen *Demodex*-blepharitis--ein fallbericht [Topical administration of metronidazole gel as an effective therapy alternative in chronic *Demodex* blepharitis--a case report]. *Klin Monbl Augenheilkd.* 1998; 213: 48-50. German.
34. Holzchuh FG, Hida RY, Moscovici BK, Villa Albers MB, Santo RM, Kara-José N, et al. Clinical treatment of ocular *Demodex folliculorum* by systemic ivermectin. *Am J Ophthalmol.* 2011; 151: 1030-4.e1.
35. Karakurt Y, Zeytun E. Evaluation of the efficacy of tea tree oil on the density of *Demodex* mites (acari: demodicidae) and ocular symptoms in patients with demodectic blepharitis. *J Parasitol.* 2018; 104: 473-8.
36. Pan S, Chen Y. A clinical study on the correlation between *Demodex* infestation and ocular surface changes in patients with meibomian gland dysfunction. *Indian J Ophthalmol.* 2021; 69: 2389-94.
37. Mergen B, Arici C, Yildiz-Tas A, Bahar-Tokman H, Tokuc E, Ozturk-Bakar Y, et al. Swabs containing tea tree oil and chamomile oil versus baby shampoo in patients with seborrheic blepharitis: a double-blind randomized clinical trial. *Eye Contact Lens.* 2021; 47: 604-10.