

Calcified Intracranial Hydatid Cyst: Case Report

Kalsifiye İnttrakraniyal Kist Hidatik: Olgu Sunumu

Ender Köktekir¹, Yavuz Erdem², Cevdet Gökçek², Mete Karatay², Ali Yılmaz², Mehmet Akif Bayar², Sua Sümer³

¹Department of Neurosurgery, Faculty of Medicine, Selçuk University, Konya, Turkey

²Department of Neurosurgery, Ministry of Health Ankara Training and Research Hospital, Ankara, Turkey

³Department of Infectious Diseases, Faculty of Medicine, Selçuk University, Konya, Turkey

ABSTRACT

We present a 26-year-old patient who did farming related work had an asymptomatic intracranial hydatid cyst. A calcified intracranial cystic mass was found on radiological investigations and the patient underwent surgery. The mass was totally excised. The histopathology result reported a hydatid cyst. There were no postoperative complications. Calcification is quite rare in cerebral hydatid cyst. The computed tomography and magnetic resonance imaging provide information that is especially useful for preoperative diagnosis. Observing membrane detachment and daughter cysts during these investigations is pathognomonic. The presence of calcification in the cyst wall and intracystic membranes indicated hydatid cyst (*Türkiye Parazitol Derg* 2011; 35: 220-3)

Key Words: Calcification, Hydatid cyst, Intracranial cyst

Received: 21.02.2011

Accepted: 04.08.2011

ÖZET

Bu çalışmada; 26 yaşında, çiftlik işleri ile uğraşan, asemptomatik intrakraniyal hidatik kisti olan bir olgu sunulmaktadır. Kafa travması nedeni ile yapılan radyolojik incelemelerde kalsifiye intrakraniyal hidatik kist saptanan hasta cerrahi tedavi ile kitlenin tamamen çıkartılması sonrası nörolojik defisiti olmadan taburcu edildi. İnttrakraniyal hidatik kistlerin kalsifikasyonu oldukça nadirdir. Bilgisayarlı beyin tomografisi ve kraniyal magnetik rezonans incelemeleri operasyon öncesi tanı için oldukça önemlidir. Radyolojik incelemeler esnasında membran detaşmanın, kist duvarında kalsifikasyonun ve kist içi membranların varlığı hidatik kist varlığına işaret eder. (*Türkiye Parazitol Derg* 2011; 35: 220-3)

Anahtar Sözcükler: Kireçlenme, Hidatik kist, İnttrakraniyal kist

Geliş Tarihi: 21.02.2011

Kabul Tarihi: 04.08.2011

INTRODUCTION

Hydatid disease is caused by the larval stage of the *Echinococcus granulosus* and is endemic in various regions of the world. The prevalence is higher in North Africa and Mediterranean countries such as Turkey, Greece and some regions of Spain and Italy and it ranges between 1-150/100.000 (1, 2). The most common localization of the

disease is the liver and lung. The intracranial involvement incidence of the cyst is 1-4%, while 1-5% of these cases show calcification (2-5). When intracranial involvement occurs, it is most commonly seen in the parietal and frontal areas, respectively. The diagnosis is usually made with clinical findings, imaging techniques and serologic tests (2, 6). We present a case of calcified hydatid cyst which was discovered incidentally.

Address for Correspondence / Yazışma Adresi: Dr. Ender Köktekir, Department of Neurosurgery, Faculty of Medicine, Selçuk University, Konya, Turkey

Phone: +90 332 241 50 00 E-mail: enderkoktekirns@hotmail.com

doi:10.5152/tpd.2011.56

CASE REPORT

A 26-year-old male patient who did farming-related work presented at our clinic with headache following a minor head trauma. The physical and neurological examinations were normal. The x-ray showed a left frontal calcified lesion (Figure 1). There was a 6x5 cm mass with homogeneous peripheral calcification in the left frontal region on cranial computed tomography (CT) (Figure 2). Magnetic resonance imaging (MRI) showed the mass to contain membranous structures and to be hyperintense. There was no perilesional edema area and no contrast enhancement (Figure 3a, b). The patient was operated on via a left frontotemporal craniotomy. The mass was strongly adherent to the dura and it was therefore opened circularly, leaving this part on the mass. The mass ruptured while being dissected from the surrounding cerebral tissue and a large amount of yellow-brown material that was viscous in character drained out. The ventricle was opened while the posterior section was being dissected and cerebrospinal fluid (CSF) was seen to come out. The mass was totally excised. There were no postoperative complications. The pathology result was hydatid cyst (Figure 4). Serological results including enzyme-linked immunoabsorbant assay (ELISA) test and indirect hemagglutination (IHA) test were negative and no other lesion was found on abdominal and thorax investigations. Culture of the cyst content sent during surgery did not grow anything. The patient was discharged on the 14th postoperative day.

DISCUSSION

Hydatid cyst involves the liver in 75% of the patients, the lung in 15% and other organs in 10% (6, 7). Central nervous system involvement is seen in 1% of the cases and is usually diagnosed in childhood. It can be located in any area of the brain but is most commonly seen at the area supplied by the middle cerebral artery in both hemispheres (most commonly in the parietal region, followed by the frontal region) (7-9). They are not symptomatic until they reach a certain size. There is usually no other focus, as in our case. Hepatic or pulmonary localization has been shown in only 10-20 % of cerebral hydatid cysts (9, 10).

The epidemiologic and clinical findings, imaging techniques and serologic tests are used to make a diagnosis (9, 11). The serologic diagnosis of hydatid cyst usually is more of a challenge in the brain than in the other organs because the antibody response is usually absent or very low in the case of intracranial hydatid cyst, especially if calcified (12). In the presented case, the serologic tests including ELISA and IHA were negative but the imaging tests were specific for an intracranial calcified hydatid cyst.

CT shows cranial hydatid cysts as intraparenchymal, homogeneous cystic lesions with distinct borders. The cyst fluid is isodense with the CSF and the cyst itself is usually circular. Noncontrast CT shows an isodense or hyperdense cyst wall compared to the brain tissue. The perilesional edema and contrast enhancement seen with abscesses or cystic tumors are unusual for hydatid cysts (7). MRI produces a similar radiological appearance. T1- and T2-weighted images show a low signal intensity rim of the cyst wall, while the cyst content is isointense with the CSF. There is mild or moderate perilesional edema in infected

hydatid cysts and there may be limited contrast enhancement in the capsule region (13, 14). Membrane detachment and daughter cyst are pathognomonic findings on CT and MRI. The presence of calcification in the cyst wall and intracystic membranes indicate a hydatid cyst (13, 14). We found calcification both on

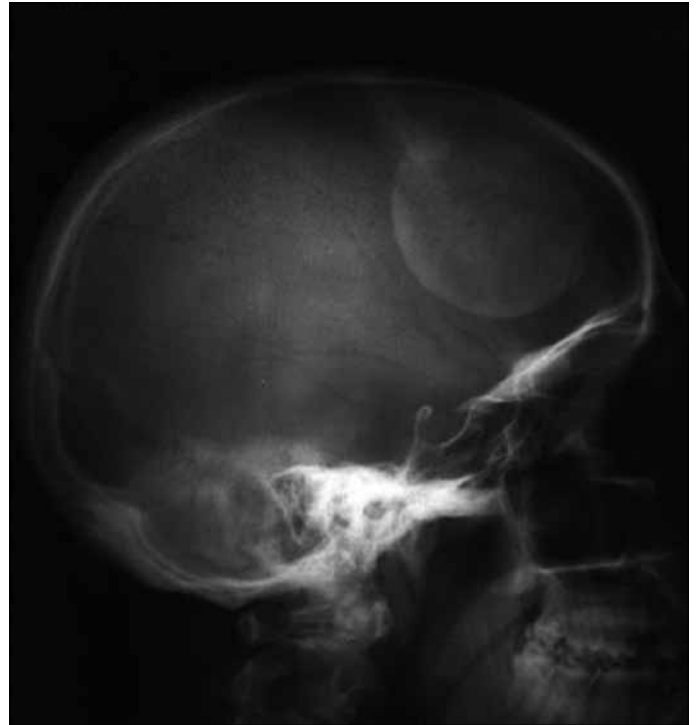

Figure 1. Calcified mass in the frontal region on direct cranial x-ray

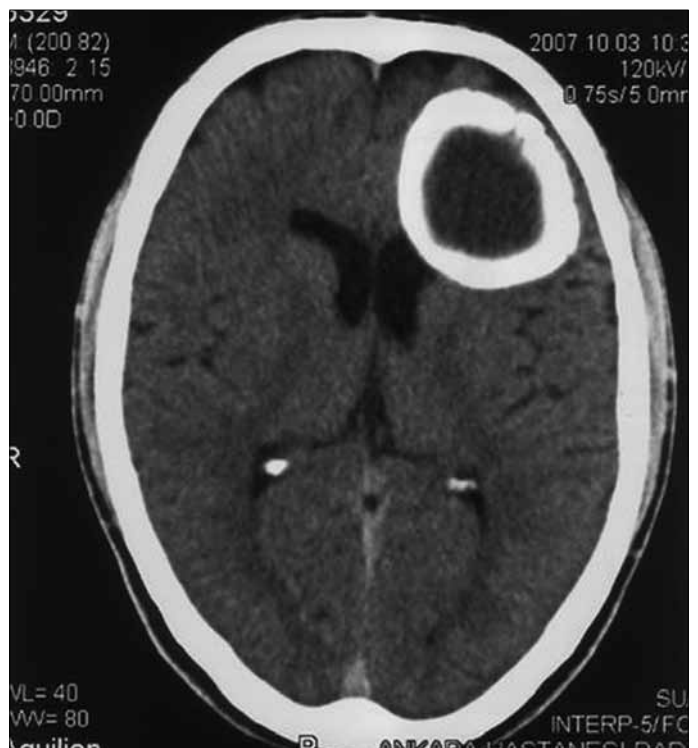


Figure 2. 6x5 cm left frontal mass with perilesional calcification on CT

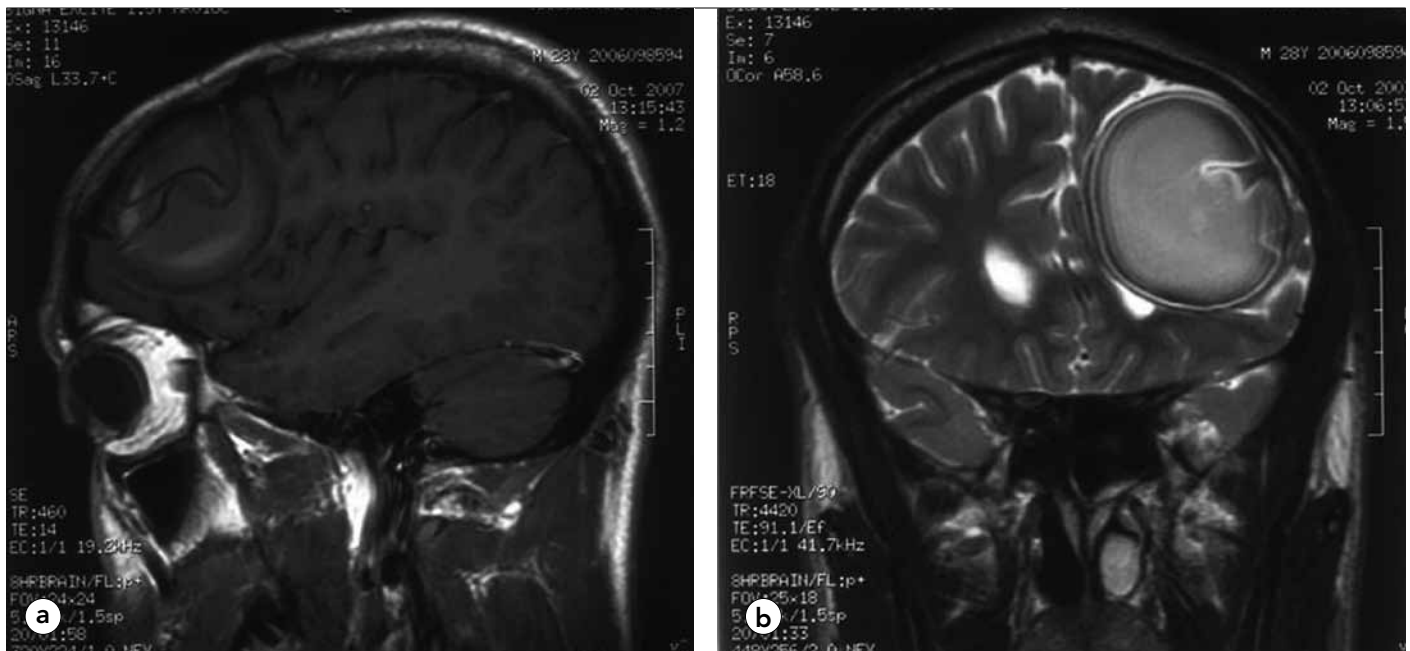


Figure 3. a) T1-weighted sagittal MRI shows intracystic membranes and b) T2-weighted coronal MRI shows membrane detachment

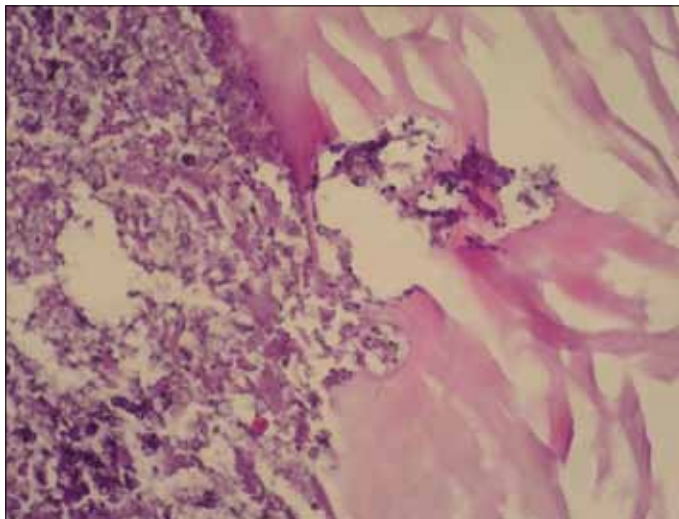


Figure 4. Degenerated and necrotic material calcified in some areas and cuticula. H&E x 400

direct cranial X-ray and CT in our case. MRI showed membrane detachment and intracystic membranes.

The incidence of calcification in hydatid cyst is 20-30% for liver localization and 1-5% for lung or liver localization (6, 7). The calcification is usually ring-like with a curvilinear pattern and develops in the pericyst consisting of modified host cells with a fibrous protective zone several mm thick. The hydatid cyst capsule consists of 3 layers with the pericysts outside, laminated membranes in the middle and germinal layer inside (15). The laminated membrane is a structure that lets nutrients pass through but stops bacteria. Damage to this membrane predisposes to infection. Calcification develops in all components of the cyst during the natural healing stage once the pericyst is calcified. The clear fluid that fills the cyst is replaced by a thick and viscous sub-

stance rich in cholesterol as in our case. Finding calcification in the pericysts does not indicate death of the parasite. Although an association has been found between pericyst calcification and cyst inactivation for hydatid cysts localized in the liver, such a classification is not available for cerebral cysts due to the low number of cases (6, 16). Complete calcification indicates death of the parasite (15).

The primarily treatment of intracranial hydatid cysts is surgical. One of the aims of treatment for hydatid cysts located in the liver is calcification of the cyst. Surgical or medical treatment is therefore accepted to be contraindicated in the case of partial or total calcification in the cyst (6). A 'wait and see' approach is recommended before any surgical intervention for hydatid cysts with homogeneous calcification in the walls and those localized in the liver (6). There is no data on whether the same approach can be used for intracranial cysts. Cases of calcified hydatid cyst in the literature have almost all presented with epileptic seizures and this approach may therefore not be appropriate for intracranial hydatid cysts (4, 5, 17-20).

In conclusion, a hydatid cyst should be considered in patients living in or coming from areas with endemic hydatid cyst disease, especially when calcification is found during radiological investigations and a membrane or detached membrane is seen inside the cyst.

Conflict of Interest

No conflict of interest was declared by the authors.

REFERENCES

1. Dakkak A. Echinococcus/hydatidosis: a severe threat in Mediterranean countries. *Vet Parasitol* 2010; 174: 2-11. [CrossRef]
2. Delibaş SB, Ozkoç S, Sahin S, Aksoy U, Akisü C. Evaluation of patients presenting with a suspicion of cystic echinococcosis to the serology laboratory of the Parasitology Department of Dokuz Eylül University Medical Faculty. *Türkiye Parazitol Dergisi* 2006; 30: 279-81.

3. Alvarez F, Blazquez MG, Oliver B, Manrique M. Calcified cerebral hydatid cyst. *Surg Neurol* 1982; 17: 163-4. [\[CrossRef\]](#)
4. Abderrahmen K, Aouidj ML, Kallel J, Khaldi MM. Calcified cerebral hydatid cyst. *Neurochirurgie* 2007; 53: 371-4.
5. Bouaziz M. Calcified cerebral hydatid cyst: a case report. 2005; 15: 129-32.
6. Pawłowski ZS, Eckert J, Vuitton DA, Amman RW, Kern P, Craig PS, et al. Echinococcosis in humans: clinical aspects, diagnosis and treatment. WHO/OIE Manual on Echinococcosis in Humans and Animals: a Public Health Problem of Global Concern 2001. pp. 20-68.
7. Pedrosa I, Saiz A, Arrazola J, Ferreiros J, Pedrosa CS. Hydatid disease: radiologic and pathologic features and complications. *Radiographics* 2000; 20: 795-817.
8. Gökalp HZ, Dinçer C, Şekerci Z, Birlir K. Cranial hydatid cysts. (Turkish) *Türk Nöroşirurji Derg* 1989; 2: 65-71.
9. Turgut M. Intracranial hydatidosis in Turkey: its clinical presentation, diagnostic studies, surgical management, and outcome. A review of 276 cases. *Neurosurg Rev* 2001; 24: 200-8. [\[CrossRef\]](#)
10. Singounas EG, Leventis AS, Sakas DE, Hadley DM, Lampadariou DA, Karvounis PC. Successful treatment of intracerebral hydatid cyst with albendazole: case report and review of the literature. *Neurosurgery* 1992; 31: 571-4. [\[CrossRef\]](#)
11. Yılmaz GR, Babur C. Ekinokokkosis tanısı. *Türk Hij Den Biyol Derg* 2007; 64: 35-44.
12. Eşgin M, Aktas M, Coskun S. The investigation of antibody presence in the sera of patients with a suspicion of cystic echinococcosis by using indirect hemagglutination test (IHA). *Türkiye Parazitoloji Dergisi* 2007; 31: 283-7.
13. Bükte Y, Kemaloglu S, Nazaroglu H, Ozkan U, Ceviz A, Simsek M. Cerebral hydatid disease: CT and MR imaging findings. *Swiss Med Wkly* 2004; 134: 459-67.
14. El-Shamam O, Amer T, El-Atta MA. Magnetic resonance imaging of simple and infected hydatid cysts of the brain. *Magn Reson Imaging* 2001; 19: 965-74. [\[CrossRef\]](#)
15. Beggs I. The radiology of hydatid disease. *AJR Am J Roentgenol* 1985; 145: 639-48.
16. WHO Informal Working Group. International classification of ultrasound images in cystic echinococcosis for application in clinical and field epidemiological settings. *Acta Trop* 2003; 85: 253-61. [\[CrossRef\]](#)
17. Choukri M, Bertal A, Lakhdar A, Achouri M, Ouboukhlik A, el Kamar A, et al. Calcified cerebral hydatid cyst. Report of a case. *J Neuroradiol* 2001; 28: 261-3.
18. Menkü A, Kurtsoy A, Tücer B, Durak AC, Akdemir H. Calcified cerebral hydatid cyst following head trauma: case report. *Türk Neurosurg* 2004; 14: 36-40.
19. Micheli F, Lehkuniec E, Giannoula R, Caputi E, Paradiso G. Calcified cerebral hydatid cyst. *Eur Neurol* 1987; 27: 1-4. [\[CrossRef\]](#)
20. Yolaş C, Gündoğdu C, Yakut C. Dead cerebral cyst hydatid. A case report. (Turkish) *Türk Nöroşirurji Derg* 1993; 3: 38-40.