

Clinical, Physiological and Serological Observations of a Human Following a Venomous Bite by *Macrovipera lebetina Lebetina* (Reptilia: Serpentes)

Bayram GÖÇMEN*¹, Huseyin ARIKAN¹, Yusuf ÖZBEL², Ahmet MERMER¹, Kerim ÇİÇEK¹

Ege University Science Faculty, ¹ Science Faculty, Department of Zoology; ²Medical School Department of Parasitology, Bornova, Izmir, Turkey

SUMMARY: A researcher, a 40 year-old male, was bitten on his finger accidentally by a 75 cm long, adult male blunt-nosed viper, *Macrovipera lebetina lebetina* (Linnaeus) that had been collected from northern Cyprus during laboratory work in the Zoology Section, Biology Department of the Ege University Faculty of Science. The clinical signs, physiological and biochemical changes soon after the venomous bite by the blunt-nosed viper as well as the electrophoretic separation of plasma proteins of the patient have been presented here. Serious important symptoms (edema, hypotension shock, hemorrhage, tissue necrosis, and melanoderma) developed and major quantitative differences in the fractions of albumin, globulin and albumin/globulin ratios were detected. On the other hand, the measurements carried out in blood smears and biochemical results indicated the decrease in RBC, MCV, MHV and a decrease in the diameter of red blood cells, as well as an increase in WBC.

Key Words: Venomous snake bite, *Macrovipera lebetina*, blunt-nosed viper, electrophoretic and biochemical analysis, blood cells

***Macrovipera lebetina lebetina* (Reptilia: Serpentes) Isırması Ardından İnsanda Klinik, Fizyolojik ve Serolojik Gözlemler**

ÖZET: Ege Üniversitesi Fen Fakültesi Biyoloji Bölümü Zooloji Anabilim Dalı'nda yürütülmekte olan bir çalışma esnasında, kuzey Kıbrıs'tan toplanan 75 cm uzunluğunda ergin erkek bir Koca engerek, *Macrovipera lebetina lebetina* (Linnaeus) tarafından kazara 40 yaşındaki erkek bir araştırmacı ısırılmıştır. Isırılmadan hemen sonra ortaya çıkan klinik belirtiler, fizyolojik ve biyokimyasal değişiklikler ile hastanın plazma proteinlerinin elektroforetik separasyonları burada sunulmuştur. Bir seri önemli semptomlar (ödem, hipotansif şok, hemoraji, doku nekrozu, melanodermi) ve albumin, globulin, albumin/globulin oranlarında kantitatif açıdan önemli farklılıklar gelişmiştir. Diğer taraftan kan yayma preparasyonlarından gerçekleştirilen ölçümler ve biyokimyasal sonuçlar RBC, MCV, MHV ve kan hücrelerinin normal boyutlarında düşüş, WBC de ise artış olduğunu göstermiştir.

Anahtar Sözcükler: Yılan ısırması, *Macrovipera lebetina*, Koca engerek, Elektroforetik ve biyokimyasal analiz, Kan hücreleri

INTRODUCTION

The venomous snakes have been widespread in tropical and subtropical regions of the world including northern Cyprus (2, 7, 13). According to the venom apparatus, *Macrovipera lebetina lebetina* is involved in solenoglyph group snakes (3, 4). The clinical and biological studies and publications have been getting increased about venoms of Colubridae family members as parallel of technological developments (5-9). In addition to these studies,

many works on pharmacological, biochemical, immunological and toxicological fields were performed using venoms obtained from snakes belonging to Viperidae, Colubridae and Elapidae families (1, 2, 9, 11, 12, 18-21). These studies reported that venoms of solenoglyph (Viperidae and Crotalidae) and opisthoglyph (Colubridae) group snakes are haemolytic-proteolytic while the venoms of proteroglyph (Elapidae and Hydrophiidae) group snakes are neurotoxic (4, 7).

There is no published study on clinical status and electrophoretic types of the changes occurred in the protein profiles of human blood, in case of biting by *Macrovipera lebetina*. During a laboratory work for determining taxonomical differences between

Geliş tarihi/Submission date: 15 Mart/15 March 2006

Kabul tarihi/Accepted date: 20 Mart/20 March 2006

Yazışma /Corresponding Author: Doç. Dr. Bayram GÖÇMEN

Tel: (+90) (232) 388 40 00 #1795 Fax: (+90) (232) 388 10 36

E-mail: bayram.gocmen@ege.edu.tr

M. lebetina lebetina and *M. lebetina obtusa* in Ege University Science Faculty Department of Zoology, a researcher was bitten from his finger accidentally by *Macrovipera lebetina* coming from northern Cyprus. In this study, the clinical symptoms, physiological, serological and biochemical developments after biting were presented.

MATERIAL AND METHODS

The researcher was bitten by an adult male and 75 cm long blunt-nosed viper (*M. lebetina lebetina*) collected from northern Cyprus. The researcher was 40 years old, male, white, 74 kg weight and 178 cm long. After envenomating;

- (i) the clinical signs were noted.
- (ii) the blood samples of the victim were taken into the hematocrit tubes in 24 hours, one and two weeks, were centrifuged in 600 g for 5 min and stored in -20 °C until use. Electrophoretic analyses were performed for each sample separately at the same time. Totally, 4 µl blood plasma samples were used for each tube for the electrophoretic analysis. The separation of blood plasma proteins was performed according to Davis's (5) method modified by Arikan et al. (1). Briefly, 7.5% separation gel (pH= 9), 2.5% stacking gel (pH= 6.7) and Tris-Glycine Buffer (pH= 8.3) were used. The electropho-

retic separation was done in room temperature using Canalco 1200 Model electrophoresis apparatus. After separation, the gels were stained 0.5% Amido Black (Naphthol Blue Black 10-B) and de-staining was done using a 7% acetic acid solution. The qualitative evaluation was done directly while Gelman ACD-15 Model 39340 densitometry (500 nm) was used in qualitative evaluation to get the percentages of protein fractions and densitometric curves, and finally albumin/globulin rates were calculated.

- (iii) The blood smears were prepared using one drop of peripheral blood taking from near finger in 24 hrs, one week and two months, were stained with Wright stain to investigate the morphological effects of snake venoms on blood cells.
- (iv) And when patient was hospitalized, the biochemical analysis was performed in one hour, 12 hours and 2 months later using automatic analyzer in Biochemistry Department of Ege University Hospital.

RESULTS

The victim's right hand finger was pricked by right tooth of the great viper (Figure 1a, b) at 16:00 o'clock and the venom was injected into the victim without showing any resistance, and the victim did not feel pain. After biting, only 1-2 drops bleeding were seen and the first main symptom was edema

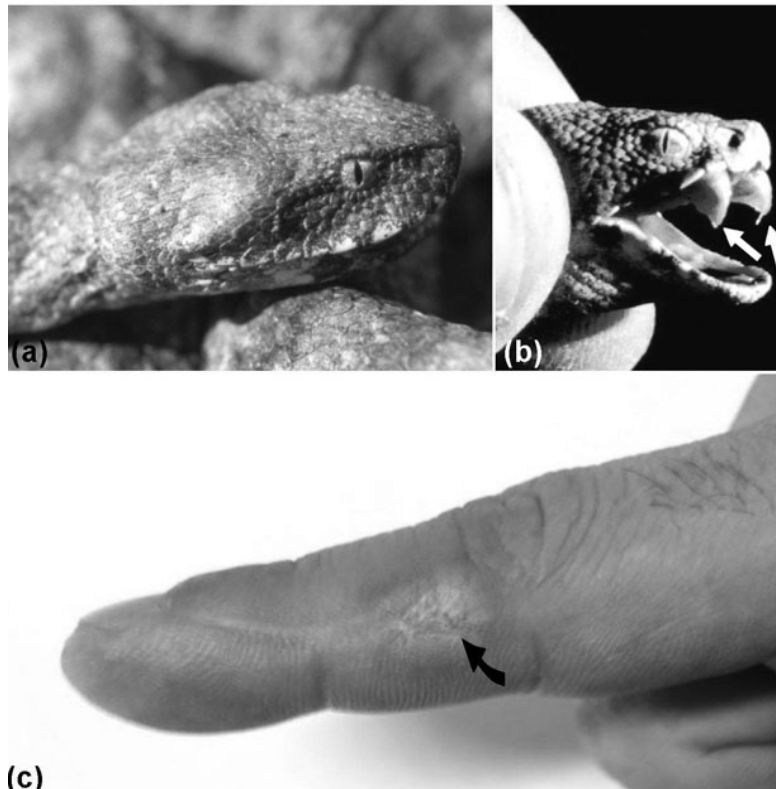


Figure 1. (a): Blunt-nosed viper, *Macrovipera lebetina lebetina*; (b): venom apparatus in a juvenile snake; (c): the view of the scar and edema (arrow).

Table 1. The values of globuline fractions and albumin/globulin ratios in 24th hrs, 1st week and 2nd weeks after biting. (A: Albumine; G: Globuline)

Time	G ₁	G ₂	G ₃	G ₄	G ₅	G ₆	G ₇	G ₈	G ₉	G ₁₀	A	A/G
In 24th hrs	7.24	5.65	4.46	14.19	6.53	2.03	3.72	6.66	6.21	6.29	36.96	0.587
In 1st week	8.40	5.77	4.67	15.48	6.17	1.25	1.81	7.37	2.94	5.40	40.67	0.686
In 2nd week	8.89	8.26	5.46	7.63	8.46	2.02	1.36	6.37	3.64	5.35	42.51	0.740
Changing	↑	↑	↑	↓	↑	↔	↓	↔	↓	↓	↑	↑

Table 2. The result of biochemical tests of the patient. (*normal values according to age and gender)

TEST	Unit	Normal Values*	In 45 mins	In 12 hrs	In 2 months
Direct Bilirubin	mg/dl	0 - 0.25	↑ 0.41	0.20	0.10
Glucose	mg/dl	< 110	↑ 144	↑ 131	↑ 112
Sodium	Meq/l	136-145	↔ 143	↔ 143	↓ 135
Potassium	meq/l	3.5 - 5.0	↓ 3.4	↔ 4.6	↔ 4.9
White blood cells (WBC)	x10 ³ /mm ³	4.5-11	↔ 9.3	↑ 17.5	↑ 20.4
Red blood cells RBC)	x10 ⁶ /mm ³	4.52 - 5.9	↑ 6.30	↑ 6.90	↑ 6.57
Hemoglobine	g/dl	13.5-17.5	↔ 16.9	↑ 18.2	17.5
Hematocrite	%	41.5-50.4	↔ 49.7	↑ 54.2	↑ 51.4
Mean Corpuscular Volume (MCV)	fl	80 - 96.1	↓ 78.8	↓ 78.5	↓ 78.2
Mean Hemoglobine Value	pg	27.5 - 33.2	↓ 26.8	↓ 26.4	↓ 26.6
Red Cell Distribution Width (RDW)	%	11.6 - 14.6	↑ 15.2	↑ 15.6	14.3
Protrombine time	sn	10-14	↔ 12	↔ 11.9	↔ 12.1
Protrombine Activity	%	70-120	↔ 104	↔ 106	↔ 102
Active Partial Tromboplastine time	sn	25.4-41.4	↔ 29.3	↔ 30.4	↔ 33.2
Plateletes	x10 ³ /mm ³	150-450	↔ 255	↔ 298	↔ 261

Table 3. The diameter of red cells in 24 hrs, 1 week and 2 months after biting (SD: standard deviation)

	Mean	Min-Max.	SD
In 24 hrs (n=25)	5.10	3.57 - 6.43	0.87
In 1 week (n=25)	8.25	6.43 - 10.00	0.75
In 2 months (n=25)	8.30	7.14 - 10.00	0.87

within 5th min. Edema has been getting increased and progressed with severe pain until the middle of the right arm within 3 hrs. In 20th minutes after biting, to remove the venom from bite site, a “venom extractor” was used and a small amount of fluid was aspirated in the color of light yellow without blood. The victim did not feel faintness but was transferred to the hospital in 30 minutes (at 16:30) and hospitalized in emergency unit for following up. The patient was started to receive physiological saline and anti-allergic drug in 45th minutes (at 16:45) by intravenously for diluting his blood (totally 1 liter in 12 hrs) and for preventing allergic reaction or anaphylactic shock. The anti-venom was not given to the patient because of its absence in the hospital. The hypotension shock was developed after 2 hrs 30 minutes (at 18:30). At the same time, uncontrolled movements of arms and legs were observed by the physicians and then he felt faintness and other symptoms were developed like, dyspnea, tachycardia, sweating and tremble. These symptoms

were disappeared in 20 minutes spontaneously. The patient was discharged from the hospital after 24 hours, because of his general condition was normal. The edema was started to decrease after 24th hrs and continued gradually, but it was still present in metacarpal and finger in 3rd week, and completely recovered after 6th week. During this period, melanodermi and itching sense was continued only in the bite site. The detectable scar in the bite site was still present even after 3 months (Figure 1c).

The electrophoretic separation and densitometric curves of plasma samples obtained in 24th hrs, 1st week and 2nd weeks as were shown in Figure 2. The plasma proteins were grouped in 10 different fractions. According to the results of serological analysis, no difference was found to be between electroferograms of blood-plasma proteins qualitatively, while major differences were found to be in the fractions of albumin, globulin and albumin/globulin ratios, quantitatively (Table 1 and Figure 2). The biochemical tests results and blood smear findings were summarized in Tables

2, 3 and Figure 3. The level of liver enzymes and total protein was found to be normal during two months, while the albumin level found to be increased at the beginning and turned to normal in a short time. While the concentration of potassium ions in the blood were found to be decreased (Table 2), the level of direct bilirubin was found to be increased in 45th min and both turned to normal in 12th hrs. The hemoglobulin and hematocrit values were found to be increased after 12 hrs.

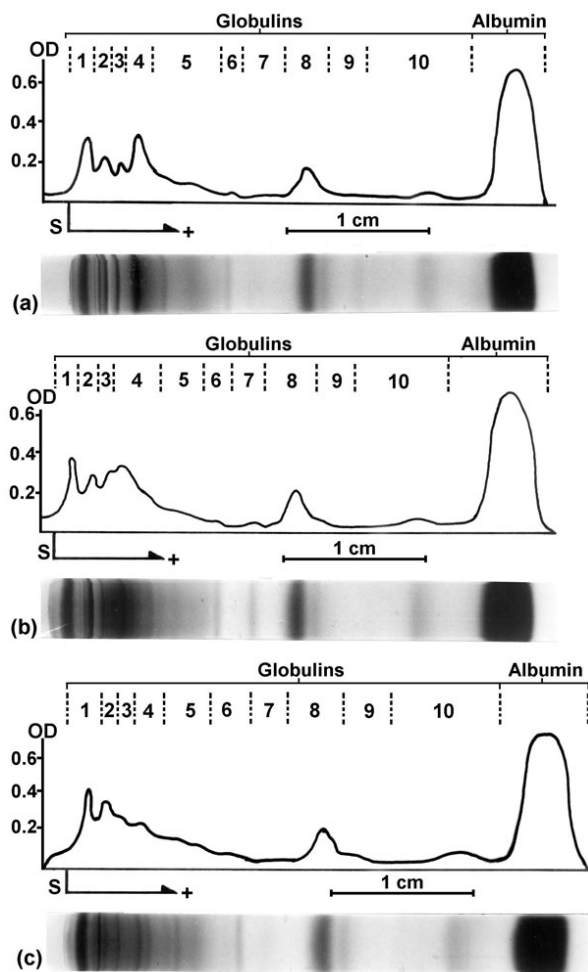


Figure 2. The pictures of gels and electroferograms showing electrophoretic separation and densitometric curves of plasma samples obtained in (a) 24th hrs, (b) 1st week and (c) 2nd weeks after biting. OD: Optical density; S: Start (junction between the spacer and separation gels).

The number of red blood cells were found to be decreased in 45th min and turned to normal in one day, and the number of white blood cells was found to be increased significantly, although mean corpuscular volume (MCV) and mean hemoglobin value (MHV) were found to be decreased. This finding has been shown that the decreasing of the diameter of red blood cells (Table 3, Figure 3a). The measurements carried out in blood smears were supported this findings with the detection of 50% decreasing of the normal size (8.30 μm) in the diameter of red blood cells

within 24th hrs (Table 3). This has been caused with undulating membrane of red blood cells (Figure 3a, b, c). In 3rd week, the appearance of white and red blood cells turned to normal (Figure 3d) but projections like spine were still present on the red blood cell surface because of the influence of the venom.

DISCUSSION

Macrovipera lebetina is one of the most venomous snakes in the East Mediterranean countries. Serious clinical problems such as edema, hemorrhage and tissue necrosis are observed in humans following *M. lebetina* envenomating (7, 8, 11, 14; 21). In this case, following *M. lebetina* envenomating, the bleeding and swelling was observed because of the edema within 5 minutes and the edema accompanying with severe pain was reached maximum level in 3 hrs. Envenomation caused by snakes produce a lesion in the bite site and can result in extensive necrosis. The dead tissue can be secondarily infected by bacteria coming from the snake, and the bacteria can be inoculated at the moment of the bite (15). But, the secondary bacterial infection did not detect in this patient and he did not receive antibiotics.

The snake venoms are affected victims with different ways according to the enzyme ingredients, and they can be neurotoxic or hemolytic (3, 4, 6, 7). The venoms of colubrid, viperid and crotalid snakes are mainly hemolytic while others (elapid and hydrophid) are mainly neurotoxic (4, 7). In the present case, detection of decreasing in the potassium level in 45th minutes after biting has been shown inhibition of stimulus transmission on post-synaptic membranes. Because of the inhibition, the patient did not feel pain at the moment of biting and soon after. This indicates that the viperid venom has also weak neurotoxic effect as shown by different authors in some viperid species, *Vipera palaestinae* and *V. aspis* (10, 16, 17). During the hypotension shock, he showed uncontrolled movements and then felt faintness. This can be because of the neurotoxic effect of viperid venom. The hemolytic effect of the venom on red blood cells was observed in blood smear preparations. The effects of venom on white blood cells were also detected first time.

The hypotension is one of the important symptom of envenomating (6), and in our case, the hypotension shock was also developed after 2hrs 30 minutes. This is probably because of the metabolic defects appearing with extracellular dehydration (edema).

The measurements carried out in blood smears were supported biochemical results (decreasing of RBC, MCV and MHV and increasing of WBC) with the detection of 50% decreasing of the normal size (8.30 μm) in the diameter of red blood cells within 24th hrs. This has been caused with undulating membrane of red blood cells. The hemoglobulin and hematocrit values were found to be increased after 12 hrs and this probably depends on increasing of the number of red blood cells and releasing of hemoglobulin into the plasma because of hemolysis.

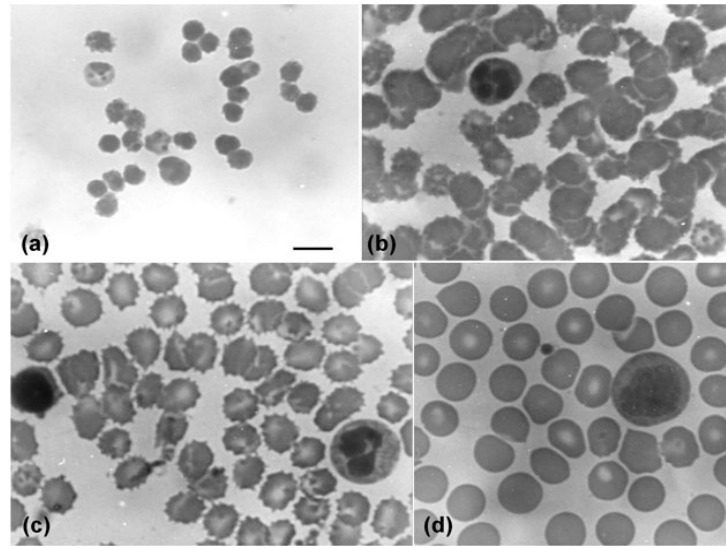


Figure 3. The picture of peripheral blood smears (Bar: 10 µm).
(a): in 24th hrs; (b): in first week; (c): in 2nd weeks; (d): in 3rd weeks.

REFERENCES

1. **Arikan H, Kumlutaş Y, Türkozan O, Baran, İ,** 2003. Electrophoretic patterns of some viper venoms from Turkey. *Turk J Zool*, 27: 239-242.
2. **Arikan H, Göçmen B, Mermer A, Bahar H,** 2005. An electrophoretic comparison of the venoms of a colubrid and various viperid snakes from Turkey and Cyprus, with some taxonomic and phylogenetic implications. *Zootaxa*, 1038: 1-10.
3. **Budak A, Göçmen B, Mermer A, Kaya U,** 2002. *Omurgalılar Sistematigi (Vertebrate Systematics)*. Ege Üniversitesi Fen Fakültesi Kitaplar Serisi No: 181, Ege Üniversitesi Basımevi, İzmir.
4. **Budak A, Göçmen B,** 2004. *Herpetoloji (Herpetology)*. Ege Üniversitesi Fen Fakültesi Kitaplar Serisi No: 194, Ege Üniversitesi Basımevi, İzmir.
5. **Davis BJ,** 1964. Disc electrophoresis II. Method and application to human serum proteins. *Ann N.Y. Acad Sci*, 28: 404-427.
6. **Dökmeci İ,** 1992. *Toksikoloji (Toxicology)*. Nobel Medical Publishing, Istanbul.
7. **Edstrom A,** 1992. *Venomous and Poisonous Animals*. Kriger Publishing Company, Malabar, Florida.
8. **Elliot WB,** 1978. Chemistry and Immunology of Reptilian Venoms. In: Gans, B.C., Ed., *Biology of the Reptilia*. Academic Press, London, p.163-436.
9. **Faiz MA, Falkous G, Harris JB, Mantle D,** 1996. Comparison of protease and related enzyme activities in snake venoms. *Comp Biochem Physiol*, 1138:199-204.
10. **Garrigues T, Dauga C, Ferquel E, Choumet V, Failloux, AB,** 2005. Molecular phylogeny of *Vipera Laurenti*, 1768 and the related genera *Macrovipera* (Reus, 1927) and *Daboia* (Gray, 1842), with comments about neurotoxic *Vipera aspis aspis* populations. *Mol Phylogenet Evol*, 35: 35-47.
11. **Gasmi A, Srairi N, Guermaji S, Dkhil H, Karoui H, El Ayeb M,** 2001. Amino acid structure and characterization of a heterodimeric disintegrin from *Vipera lebetina* venom. *Biochimica et Biophysica Acta*, 2001; 1547: 51-56.
12. **Girons SH, Detrait J,** 1992. Electrophoretic analysis of *Vipera* venoms (subfamily Viperinae) variability of protein pattern and phylogenetic implications. *Bull Soc Zool De France*, 117: 399.
13. **Göçmen B, Tok CV, Kaya U, Tosunoğlu M,** 1996. Kuzey Kıbrıs'ın herpetofaunası hakkında bir ön çalışma raporu [A preliminary report on the herpetofauna of Northern Cyprus]. *Turk J Zool*, 20:161-176.
14. **Huang SY, Perez JC,** 1980. Comparative study on and proteolytic activities of snake venoms. *Toxicon*, 18: 421-426.
15. **Jorge MT, Riberio LA,** 1997. Infections in the bite site after envenoming by snakes of *Bothrops* genus. *J Venom Anim Toxins*, 3:74-76.
16. **Kochva E,** 1987. The origin of snakes and evolution of the venom apparatus. *Toxicon*, 25: 65-106.
17. **Kochwa S, Perlmutter CH, Gitter S, Rechnic J, Vries A,** 1960. Studies on *Vipera palaestinae* venom, fractionation by ion exchange chromatography. *Ann J Trop Med Hyg*, 9: 374.
18. **Kornalik F, Taborska E, Mebs D,** 1978. Pharmacological and biochemical properties of a venom gland extract from the Snake *Thelotornis kirtlandi*. *Toxicon*, 16: 535-542.
19. **Minton SA, Weinstein SA,** 1987. Colubrid snake venoms; immunologic relationships, electrophoretic patterns. *Copeia*, 4: 993-1000.
20. **Sarray S, Srairi N, Luis J, Marvaldi J, El Ayeb M, Marrakchi N,** 2003. Lebecetin, a potent antiplatelet C-type lectin from *Macrovipera lebetina* venom. *Biochimica et Biophysica Acta*, 1651: 30-40.
21. **Tun-Pei Nu-Nu-Lwin, Aye-Aye-Myint, Kyi-May-Htwe, Aung-Cho,** 1995. Biochemical and biological properties of the venom from Russell's viper (*Daboia russelli siamensis*) of varying ages. *Toxicon*, 33: 817-821.